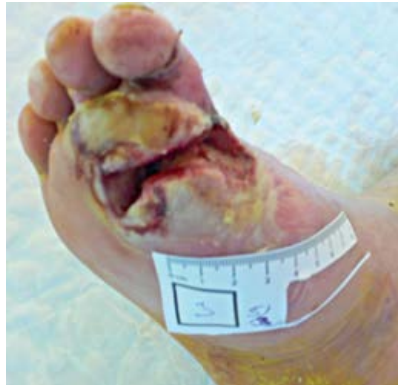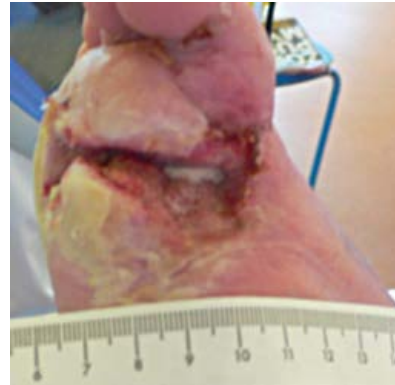


Case Study 6: Infected Foot Wound

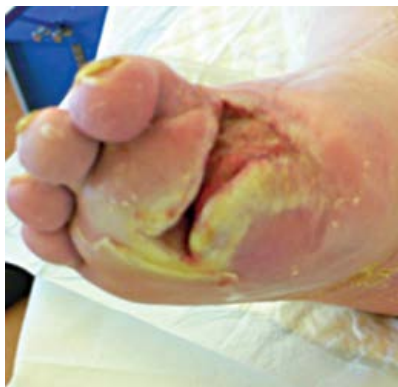A 74-year-old male with hypertension presented with an infected (limited growth of *Morganella morganii* and *Staphylococcus aureus* along with moderate growth of *Bacteroides fragilis*) neuropathic wound located on his right foot. After adequate debridement, V.A.C. VeraFlo™ Therapy was initiated using V.A.C. VeraFlo™ Dressing. Lactated Ringer's Solution (10mL) was instilled, followed by a soak time of 15 minutes. Instillation was repeated every 3.5 hours, followed by continuous negative pressure at -125 mmHg for 9 days. No complications occurred during therapy, and granulation tissue was present with no signs of infection based on clinical and culture results. The wound was then treated with V.A.C.® Therapy.



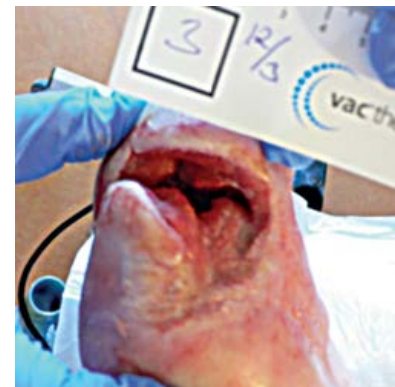A. Wound at initial presentation



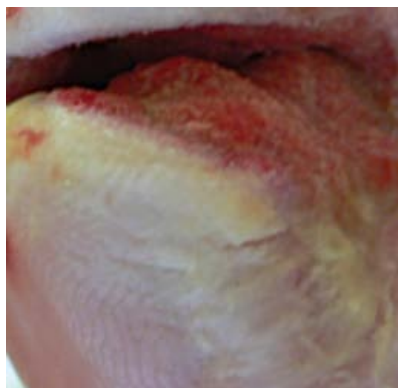
B. First dressing change



C. Second dressing change



D. Third dressing change



E. Wound after 9 days of V.A.C. VeraFlo™ Therapy